

SPECIAL ARTICLE

Neonatal multiple organ failure after perinatal asphyxia



Isabel Iribarren, Enrique Hilario, Antonia Álvarez, Daniel Alonso-Alconada*

Departamento de Biología Celular e Histología, Facultad de Medicina y Enfermería, Universidad del País Vasco/Euskal Herriko Unibertsitatea (UPV/EHU), Leioa, Bizkaia, Spain

Received 10 May 2022; accepted 5 August 2022
Available online 14 September 2022

KEYWORDS

Asphyxia;
Neonate;
Multiple organ failure;
Kidney;
Liver;
Gastrointestinal tract;
Heart

Abstract Perinatal asphyxia is an event with far-reaching consequences that can lead not only to the development of neonatal encephalopathy, but also to multiple organ failure (MOF). This ailment may result from the redistribution of blood flow, which would preserve the perfusion of vital organs such as the heart, brain and adrenal glands at the expense of other organs.

The objective of the study was to determine the incidence and aetiopathogenesis of failure in the organs most frequently involved in neonatal MOF following perinatal asphyxia.

We conducted a systematic literature search in the PubMed, Scopus and Cochrane Library databases using the MeSH terms (*ischemia AND hypoxia AND multiorgan dysfunction AND neonat**), (*asphyxia AND multiorgan dysfunction AND neonat**) and (*liver/kidney/digestive OR gastrointestinal/heart injury AND ischemia AND hypoxia AND neonat**). We selected clinical and preclinical studies published after 2000 and excluded case series, letters to the editor, cohort studies without comparison groups and abstracts.

In this study, we found that MOF associated with perinatal asphyxia is a frequent phenomenon with a relevant impact on neonatal morbidity and mortality, as it can cause changes not only in the kidney, liver and gastrointestinal tract, but also cardiomyopathy if the ailment is protracted or severe.

© 2022 Asociación Española de Pediatría. Published by Elsevier España, S.L.U. This is an open access article under the CC BY-NC-ND license (<http://creativecommons.org/licenses/by-nc-nd/4.0/>).

* Corresponding author.
E-mail address: daniel.alonsoa@ehu.eus (D. Alonso-Alconada).

PALABRAS CLAVE

Asfixia;
 Neonato;
 Fallo multiorgánico;
 Riñón;
 Hígado;
 Tracto
 gastrointestinal;
 Corazón

Fallo multiorgánico neonatal tras asfixia perinatal

Resumen La asfixia perinatal es un acontecimiento con efectos de gran alcance, pudiendo conducir no solo al desarrollo de encefalopatía neonatal, sino también a un fallo multiorgánico (FMO). Esta afectación posiblemente se deba a la redistribución del flujo sanguíneo, mediante el cual se conserva la irrigación de órganos vitales como el corazón, el cerebro y las glándulas suprarrenales, a expensas de su disminución en otros órganos.

El objetivo del presente trabajo fue conocer la incidencia y la etiopatogenia de los órganos más frecuentemente afectados en el FMO neonatal tras la asfixia perinatal.

Se realizó una búsqueda bibliográfica sistemática en las bases de datos Pubmed, Scopus y The Cochrane Library empleando los términos MeSH (*ischemia AND hypoxia AND multiorgan dysfunction AND neonat**), (*asphyxia AND multiorgan dysfunction AND neonat**) y (*liver/kidney/digestive OR gastrointestinal/heart injury AND ischemia AND hypoxia AND neonat**). Se incluyeron trabajos clínicos y preclínicos posteriores al año 2000 y se excluyeron series de casos, cartas al director, cohortes sin grupo comparador y abstracts.

En el presente trabajo describimos que el fallo multiorgánico asociado a la asfixia perinatal es un fenómeno frecuente y relevante en la morbimortalidad del neonato, pudiendo llegar a producir no solo alteraciones en riñón, hígado y tracto gastrointestinal, sino también miocardiopatía si el fenómeno se prolonga o es de elevada gravedad.

© 2022 Asociación Española de Pediatría. Publicado por Elsevier España, S.L.U. Este es un artículo Open Access bajo la licencia CC BY-NC-ND (<http://creativecommons.org/licenses/by-nc-nd/4.0/>).

Introduction

The incidence of perinatal asphyxia continues to be relatively high in live births (1‰ to 6‰).¹ Perinatal asphyxia refers to a process characterised by progressive hypoxia, hypercapnia and acidosis,² resulting in a transient but potentially harmful oxygen deprivation. The chief and most severe potential complication is the development of hypoxic-ischaemic encephalopathy (HIE), which, with an incidence of 2.5 per 1000 live births,³ is a severe disease associated with significant morbidity and mortality.⁴

During asphyxia, to preserve adequate perfusion and oxygenation of the brain, heart and adrenal glands, the cardiac output is redistributed at the cost of reducing the irrigation of other organs, possibly leading to secondary damage in the latter.^{2,5,6} This is one of the main causes considered in the case of multiple organ dysfunction (MOD) resulting from the interruption of placental flow.^{2,5} If the flow reduction persists in time, local vasoconstriction may cause cell damage and inadequate tissue function, causing postnatal dysfunction.^{5,6} Shah et al⁶ found that all infants that had HIE secondary to severe asphyxia exhibited manifestations of dysfunction of at least one organ or system, in addition to the central nervous system. Thus, perinatal asphyxia and any subsequent MOD may be associated with a high risk of lifelong severe complications that need to be taken into account.⁷

Material and methods

We conducted a systematic review using the PubMed search engine, which provides access to different literature databases compiled by the National Center for Biotechnol-

ogy Information in the National Library of Medicine, Scopus and the Cochrane Library. We included clinical and preclinical studies published after 2000 and excluded case series, letters to the editor, cohort studies without a comparison group and summaries or abstracts.

In an initial search, we used *asphyxia* [MeSH Terms] AND *multiorgan dysfunction AND neonat**. We read the abstracts of the search results to determine whether the articles focused specifically on multiorgan dysfunction after perinatal asphyxia, that is, whether they could include relevant data or, on the contrary, they were not suitable to include in the review. We selected 11 articles.

While the selected articles provided a general perspective from which to start developing the review, they did not provide sufficient data on each particular organ, so we decided to do additional searches for each of the organs of interest. The organs selected for this purpose were the liver, kidney, gastrointestinal tract and heart. This selection was based on the frequency with which each of them were affected after perinatal asphyxia and their potential contribution to neonatal morbidity and mortality. We did not include data on central nervous system abnormalities, as brain injury, while very important, is well-known in this context and the purpose of our work was to describe how other organs were affected post asphyxia.

The terms included in the second search on the different organs were *liver* [MeSH Terms]/*kidney* [MeSH Terms]/*digestive OR gastrointestinal/heart* [MeSH Terms] *injury* [MeSH Terms] AND *ischemia* [MeSH Terms] AND *hypoxia* [MeSH Terms] AND *neonat**, once again limiting the search to articles published between 2000 and 2021. The process of article selection in this search was the same applied in the previous one, starting with the perusal of the abstracts and, in the case the article focused specifically

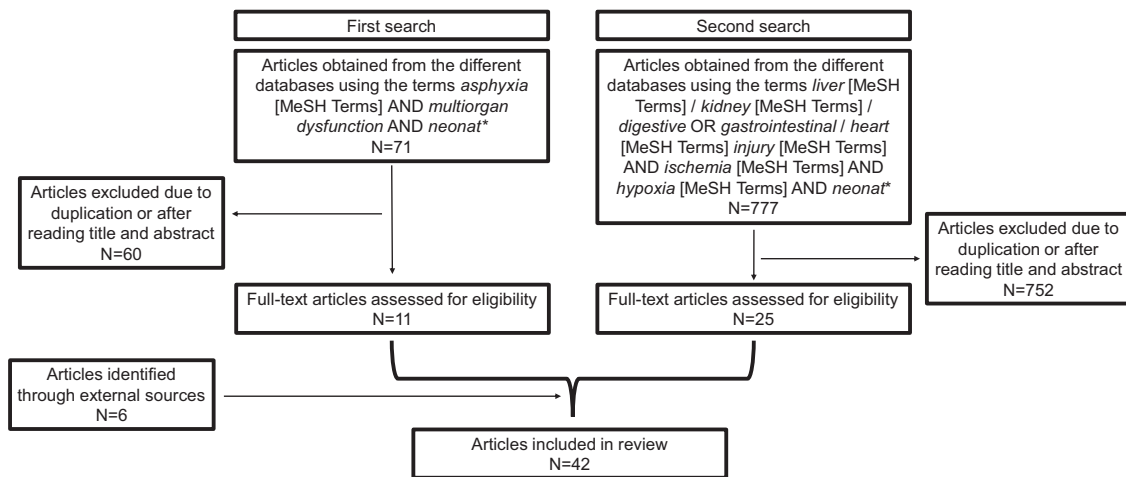


Figure 1 Flow chart of article selection in literature review.

on the subject of multiorgan dysfunction after perinatal asphyxia and/or included data relevant to the review (incidence, aetiology, pathological/histological correlates and/or biomarkers), reading of the full text. After excluding duplicates already selected in the first search and articles unrelated to the subject under study, and having added articles from external sources, the final selection for the review included a total of 42 articles (Fig. 1). The entire search and result review process was performed in duplicate. Disagreements between authors were resolved by consensus.

Multiple organ dysfunction following perinatal asphyxia

We now proceed to present the information found in the literature about the organs most frequently affected following perinatal asphyxia.

Kidney

Incidence

The incidence of renal injury in term newborns that experience perinatal asphyxia is substantial (50%–72%), and this complication is associated with an increased risk of mortality. It should be noted that there are no fixed criteria to determine its presence. The usual approach relies on the elevation of urea and creatinine levels associated with a decreased urine output,⁸ although it is important to remember that creatinine levels do not usually increase until 25%–50% of renal function is lost, and that renal failure is not always accompanied by oliguria.^{5,8}

Kidney injury and its aetiology

Despite the significant incidence of renal injury, few studies have assessed the changes undergone by the kidney. Before birth, the high renal vascular resistance, high activity of plasma renin and low glomerular filtration rate, among other factors, make this organ particularly sensitive to hypoperfusion. The main type of renal injury is acute tubular necrosis and, in more extreme cases, diffuse renal cortical necrosis.⁸ Prolonged hypoperfusion may not only reduce glomerular

filtration, but also damage cells with a higher energy consumption (tubular cells), causing necrosis of the proximal tubule and the ascending loop of Henle. In addition, the infiltration of neutrophils circulating in the ischaemic renal tissue and the release of cytotoxic substances may promote damage not only in endothelial cells but throughout the kidney.⁹

In an *in vitro* study of human proximal renal tubule cells subjected to hypoxia followed by reoxygenation, Du et al¹⁰ found a lower number of viable cells and an increased lactate dehydrogenase activity. The authors concluded that the integrity of the membrane is compromised by hypoxic episodes and that tubular cells may suffer irreversible damage. In a newborn pig model, Satas et al¹¹ detected the presence of renal infarction secondary to hypoxia-ischaemia.

Based on the Kidney Disease: Improving Global Outcomes (KDIGO) guidelines,¹² the AWAKEN study defined acute kidney injury in newborns as an increase in serum creatinine by 0.3 mg/dL or greater (26.5 μ mol/L) or to 1.5 times the baseline value or more, and/or a urine volume of less than 1 mL/kg/hour in days 2–7 post birth.¹³ In this study, the serum creatinine threshold used to define stage 3 kidney injury was 2.5 mg/dL (221 μ mol/L) rather than the 4.0 mg/dL (353.6 μ mol/L) applied in adults.^{12,13} Predictive tools have also been developed, such as the renal angina index, which aims to identify children at risk of acute kidney injury lasting more than 72 h beyond functional impairment. The clinical signs of injury are based on changes in the estimated creatinine clearance or the percentage of fluid overload.¹⁴ The neonatal STARZ score, developed recently, is used for quick quantitative assessment of the risk of acute kidney injury in newborns admitted to the neonatal intensive care unit (NICU) by means of variables such as age at admission, gestational age, sepsis, significant cardiac disease, urine output, serum creatinine and the use of nephrotoxic drugs, furosemide or inotropes.¹⁵

When it comes to newborns with neonatal encephalopathy treated with therapeutic hypothermia, there is substantial heterogeneity in renal function and injury. Some authors have asserted that serum creatinine values relative to postnatal age may provide relevant information for the

management of these infants.¹⁶ Other studies have assessed the predictive value of several urine markers of acute kidney injury: while the levels of neutrophil gelatinase-associated lipocalin, kidney injury molecule-1 and interleukin-18 were found to be elevated in newborns with HIE managed with therapeutic hypothermia who developed acute kidney injury, due to the substantial variability in their levels and poorly defined thresholds their clinical usefulness is unclear.¹⁷

Electrolyte imbalances

Asphyxiated newborns are at risk of developing hyponatraemia secondary to oliguric acute kidney injury due to water retention and a decrease in sodium reabsorption at the tubular level.⁸ They may also develop syndrome of inappropriate antidiuretic hormone, which can contribute to the development of hyponatraemia, considerable increase in weight, decreased serum osmolality considerable, oliguria and/or increased urine osmolality.^{2,8}

An important aspect to consider in these newborns at higher risk of hyperkalaemia due to renal failure is the increase in cardiac excitability.⁸ This cardiac abnormality can be exacerbated by hypocalcaemia.² Magnesium levels may also be abnormal, either reduced or elevated,⁸ with evidence of low levels in the polyuric phase of acute tubular necrosis.²

Liver

Liver damage seems to be mostly associated with hypoperfusion secondary to blood flow redistribution as opposed to hypoxia itself,⁵ as the decreased perfusion of the liver parenchyma, especially in the right lobe,¹⁸ can cause hypoxic hepatitis.¹⁹

Incidence

There is evidence of an association between perinatal asphyxia and liver damage, although the reported incidence varies widely (22%–80%) (Table 1). Hankins et al.²⁰ reported the highest incidence (80%), although this figure could be related to the severity of the cases in the study, as patients had to have developed encephalopathy after the asphyxia episode to be included. In a later study,²¹ nearly 50% of newborns had not developed HIE. However, both studies applied less stringent criteria to define liver damage compared to other studies, like the one by Tarcan et al.,²² in which the levels of alanine aminotransferase had to exceed 100 U/L, or the one by Barnett et al.,²³ in which the peak values of alanine aminotransferase or aspartate aminotransferase had to be 200 U/L or greater at 48 h. Possibly as a result of this, the incidence reported in these studies was of 39% and 22%, respectively. Furthermore, the latter one included neonates that had died of perinatal asphyxia, which is indicative of the severity of the asphyxia event in the neonates included in the sample.

This variation in the incidence could be explained not only by discrepancies in the definition of liver damage, but by the inclusion criteria applied in each study. It is also worth noting that liver damage may be underdiagnosed if liver markers are used for its identification, for, while there is a correlation between liver enzyme levels and liver damage,²¹

normal levels of transaminases or lactate dehydrogenase do not rule out damage.

Histological correlates of liver damage

In a study of 19 newborn pigs, Karlsson et al.²⁴ found foci of necrosis in 5 animals, infarction in 6, neutrophil infiltration in 6, thrombi in the intrahepatic portal veins in 3 and subcapsular haematoma in 1. Ikeda et al.¹⁸ reported detection of cytoplasmic eosinophilia and canalicular cholestasis in samples obtained from asphyxiated lambs and fatty changes in tissue samples from lambs that suffered mild asphyxia. Two brain-damaged lamb foetuses had fatty changes and congestion in the liver, in addition to inflammatory cell infiltration and centrilobular necrosis.

In the pathological examination of infants that died of post-asphyxial HIE, Barnett et al.²³ detected congestion in 22, fatty changes in 13, haemorrhage in 4, centrilobular necrosis in 7 and other necrotic-ischaemic changes in 2.

Although there is evidence that progression to complete hepatic failure is rare,²¹ there is also evidence that hepatic involvement is associated with a high mortality.²²

Coagulation abnormalities

In infants that have experienced perinatal asphyxia, the prothrombin time and the international normalized ratio are significantly elevated,^{19,21} and there is a risk of haemorrhage if there are additional alterations, such as a lower platelet count or decreased fibrinogen level.⁵

The liver synthesises a large part of the proteins involved in coagulation, but the mechanism by which hypoxia leads to bleeding is not well understood. Thus, it may be reasonable to expect coagulation disturbances if liver function is impaired.¹¹ However, Chadd et al.,²⁵ in a case-control study that included 47 term newborns, found that neonates that had experienced hypoxia exhibited coagulation abnormalities compared to controls, and that the source of the disturbance was the consumption of clotting factors, that is, disseminated intravascular coagulation. Similar results have been described by Chessells and Wigglesworth²⁶ in 9 infants that suffered severe hypoxia, suggesting that direct liver damage would play a secondary role.

Gastrointestinal tract

Incidence

Perinatal asphyxia may result in decreased perfusion of the gastrointestinal tract, manifesting with vomiting, diarrhoea, gastrointestinal haemorrhage and even necrotising enterocolitis (NEC).⁴ The incidence of these events is 29%.²⁷

The intestine is one of the organs most sensitive to ischaemia,²⁷ as it has areas located between two major arteries (mesenteric arteries) that are prone to injury secondary to perinatal asphyxia.⁵ In addition, intestinal injury is not caused only by ischaemia, but also by reperfusion.²⁷

In addition to an underdeveloped regulation of vascular resistance, the immature intestine has increased metabolic demands. This can cause problems in episodes of cardiovascular stress, as the immature body may not be able to increase intestinal blood flow and metabolic demands may overwhelm the infant's ability to increase oxygen consumption. This results in defective pressure flow autoregulation in

Table 1 Variation in the incidence of liver damage between studies.

Reference. Type of study	Incidence	Sample	Biomarkers	Criteria for liver damage
Choudhary et al., 2015 Prospective case (n = 70) and control (n = 30) study in newborns	42.85%	14.28% HIE stage I, 25.73% HIE stage II, 11.42% HIE stage III, 48.57% normal	ALT, AST, AP, LDH, total protein, serum albumin, PT, INR	ALP > 50 U/L, AST > 140 U/L, AP > 420 U/L, LDH > 580 U/L, Total protein < 4.5 g/dL, Serum albumin < 2.5 g/dL, PT > 20 s And/or INR > 1.2
Karlsson et al., 2009 Preclinical model in pigs (n = 19)	63.16%	45-min global hypoxia-ischaemia insult followed by 72-h survival	4 histological sections from standardised areas in the liver	Damage observed in the histological section
Tarcan et al., 2007 Retrospective cohort study in newborns (n = 56)	39%	Newborns admitted to the neonatal intensive care unit with a diagnosis of perinatal asphyxia	ALT	Elevation of ALT to twice the upper limit of normal (approx. > 100 U/L)
Karlsson et al., 2006 Case (n = 26) and control (n = 56) study in newborns	46%	Asphyxiated term newborns with 5-min Apgar score < 7	AST, ALT, LDH, GGT, albumin, total and conjugated bilirubin, cholinesterase activity, INR, blood cell counts	Elevation of AST or ALT more than 2 standard deviations above the mean of the control group, peaking more than 24 h after birth, and subsequent decrease to values near normal at 10 days
Barnett et al., 1997 Retrospective cohort study in newborns (n = 58).	22%	Deceased after perinatal asphyxia	ALT, AST	Peak ALT or AST values \geq 200 U/L in the first 48 h post birth
Hankins et al., 2002 Prospective cohort study (n = 46)	80%	Newborns had to have encephalopathy post asphyxia	AST, ALT, LDH	AST or ALT or LDH value \geq 1.5 times the value in control group

The table presents the reference for each article, the type of study, incidence, main sample inclusion criteria and the markers and criteria for definition of liver used in each study. ALT, alanine aminotransferase; AP, alkaline phosphatase; AST, aspartate aminotransferase; GGT, gamma-glutamyl transferase; INR, international normalised ratio; LDH, lactate dehydrogenase; PT, prothrombin time.

response to hypotension, leading to tissue hypoxia.²⁸ Thus, gastrointestinal complications are among the chief disturbances present in the context of perinatal asphyxia, with a pattern of intestinal injury similar to that found in NEC.²⁹

Necrotising enterocolitis

Necrotising enterocolitis is a potentially devastating acquired intestinal disorder in preterm infants. Its incidence in very low birth weight infants is 7%, and it is associated with a high mortality (15%–30%) and substantial morbidity.^{29–32} It is characterised by intestinal inflammation and ischaemia and changes in intestinal microcirculation.^{35,36}

Aetiology and pathogenesis. The aetiology of NEC is not well established, although it seems that the main risk factors are enteral feeding, pathogen colonization and systemic hypoxia, among others, triggering a severe inflammatory response that affects the immature intestinal epithelium of the neonate.^{28,33} Enteral feeding may increase oxygen demands past the available supply in the neonatal intes-

tine, resulting in partial hypoxia. There are reports of cases of NEC associated with ischaemic events, which, combined with the increased frequency of this disorder in areas of the intestine that are more sensitive to ischaemia due to their location between the inferior and superior mesenteric arteries (such as the distal ileum and proximal colon), suggests that this disorder is associated with circulation abnormalities.^{28,33}

In a rat model, Balyemez et al³⁰ concluded that the observed microscopic lesions were virtually the same as those described in neonatal NEC: severe destruction of villi and crypts in the intestinal mucosa.

Heart

When the interruption of placental blood flow is severe or prolonged and compensatory mechanisms are overwhelmed, the decreased cardiac output and the drop in the mean arterial pressure result in decreased blood flow in the brain

and organ systems, increasing the likelihood of ischaemic injury.^{2,34,35}

Aslam and Molloy³⁶ included the heart among the organs most frequently affected by asphyxia, likely due to the immaturity of muscle tissue in the newborn, which would result in an inadequate response to the asphyxia event. In addition, cardiac dysfunction further complicates the already compromised circulatory status.³⁵

Incidence

Hypoxic-ischaemic myocardial injury is increasingly contemplated as a potential cause of cardiovascular dysfunction in newborns, as it is present in up to one third of affected infants and could contribute to an increase in neonatal morbidity and mortality.^{7,37} Hankins et al.²⁰ conducted a cohort study on acute perinatal asphyxia followed by encephalopathy and found that 78% of cases were associated with cardiac injury, defined as inotrope requirement after 2 h post birth and/or elevation of creatinine kinase-MB. Meanwhile, Shah et al.⁶ found an incidence of 62%, in contrast to the 29% established by Martín-Ancel et al.²⁷

Markers of cardiac damage

When the heart is affected by the asphyxia event, a transitory myocardial ischaemia may develop that is known as hypoxic cardiomyopathy. A cohort study was conducted to determine the frequency of this disorder in newborns with cardiovascular symptoms, finding an incidence of 70% in newborns with perinatal asphyxia.³⁸

One of the markers used to assess for the presence of myocardial injury is creatine kinase-MB.^{14,37,39} However, other authors consider that this biomarker offers a low specificity for in newborns, as enzyme levels decrease considerably from 24 h after the asphyxia event.³⁸ Therefore, normal values of this isoenzyme do not reliably rule out myocardial injury.²⁷ Other sensitive indicators are troponin-T, troponin-I and brain natriuretic peptide.^{39,40}

Using these markers and other diagnostic methods, such as electrocardiography chest radiography, makes early detection of myocardial injury possible. This is of utmost importance, as evidence has emerged that transitory myocardial ischaemia secondary to perinatal asphyxia is more frequent than previously expected.³⁸ Early diagnosis of myocardial injury can help guide management, thus improving neonatal outcomes.^{38,40}

Cardiac function

In an observational study in neonates with severe asphyxia, Barberi et al.³⁷ found that, in addition to elevation of cardiac enzymes and relevant ischaemic electrocardiographic changes, patients also had depressed ventricular function.

Hochwald et al.⁴¹ compared left ventricular cardiac output in neonates with HIE and healthy neonates, and found a decrease of 42.34% in the former. Gurgul et al.³⁴ found that in newborn rat pups, contractile force was only affected in the ventricles.

Mitochondrial abnormalities

The incidence of myocardial injury established based on histological findings after perinatal asphyxia appears to be higher compared to estimates based on clinical man-

ifestations. Gurgul et al.³⁴ examined cardiac cells with electron microscopy and found degenerative changes in some myocardial cells that exhibited thinning and rupture of myofibrils, as well as degenerative mitochondrial changes. Yang et al.⁴² demonstrated that these alterations in mitochondria were reflected in their function, as the mitochondrial respiratory chain in myocardial cells was affected, probably due to an intracellular calcium overload.

Conclusion

Asphyxia is a phenomenon with a significant prevalence. One of the most frequent complications secondary to asphyxia is MOD, and volume redistribution is its main cause. Prolonged and/or severe episodes of perinatal asphyxia may cause cardiomyopathy.

There are difficulties that pose barriers to establishing a narrow incidence range for the involvement of each organ in the context of MOD in perinatal asphyxia. This is why the establishment of standardised criteria is considered necessary to homogenise the results of different studies.

Future perspectives

Establishing definitions for dysfunction for each organ and criteria to diagnose MOD would be useful, as there is significant variability in their reported incidence in the studies that focus on the subject. Also, more studies are required to determine the incidence of the observed gastrointestinal complications.

With the evident association between perinatal asphyxia and MOD, having been demonstrated, it may be interesting to delve into the specific management of each affected organ in asphyxiated neonates, and its performance.

It would be interesting to investigate how therapeutic hypothermia affects different organs, as, at present, it is the only authorised treatment effective in reducing the sequelae of HIE after perinatal asphyxia.

Although there are significant differences in anatomy and physiology between male and female individuals, and differences in severity and response to treatment based on sex have already been described in other diseases, there is a dearth of data on the effect of sex on MOD.

Funding

The study was funded by grants from the EITB Maratoia-BIOEF (BIO18/IC/003) and the Spanish Ministry of Science and Innovation (MINECOR20/P66/AEI/10.13039/501100011033).

Conflict of interests

The authors declare that they have no conflict of interest.

References

1. De Haan M, Wyatt JS, Roth S, Vargha-Khadem F, Gadian D, Mishkin M. Brain and cognitive-behavioural development after asphyxia at term birth. *Dev Sci.* 2006;9:350–8.

2. Stola A, Perlman J. Post-resuscitation strategies to avoid ongoing injury following intrapartum hypoxia-ischemia. *Semin Fetal Neonatal Med.* 2008;13:424–31.
3. Graham EM, Ruis KA, Hartman AL, Northington FJ, Fox HE. A systematic review of the role of intrapartum hypoxia-ischemia in the causation of neonatal encephalopathy. *Am J Obstet Gynecol.* 2008;199:587–95.
4. Thornton KM, Dai H, Septer S, Petrikin JE. Effects of whole body therapeutic hypothermia on gastrointestinal morbidity and feeding tolerance in infants with hypoxic ischemic encephalopathy. *Int J Pediatr.* 2014:1–7.
5. Polglase GR, Ong T, Hillman NH. Cardiovascular alterations and multiorgan dysfunction after birth asphyxia. *Clin Perinatol.* 2016;43:469–83.
6. Shah P, Riphagen S, Beyene J, Perlman M. Multiorgan dysfunction in infants with post-asphyxial hypoxic-ischaemic encephalopathy. *Arch Dis Child Fetal Neonatal Ed.* 2004;89:152–5.
7. Armstrong K, Franklin O, Sweetman D, Molloy EJ. Cardiovascular dysfunction in infants with neonatal encephalopathy. *Arch Dis Child.* 2012;97:372–5.
8. Sweetman DU, Molloy EJ. Biomarkers of acute kidney injury in neonatal encephalopathy. *Eur J Pediatr.* 2013;172:305–16.
9. Xiong T, Dong W, Fu H, Li Q, Deng C, Lei X, et al. Involvement of the nuclear factor- κ B pathway in the adhesion of neutrophils to renal tubular cells after injury induced by neonatal postasphyxial serum. *Mol Cell Biochem.* 2014;388:85–94.
10. Du Y, Dong W, Wang M, Hang Y. Replication of a model of injury to human renal proximal tubular cells induced by hypoxia/reoxygenation. *Zhongguo Wei Zhong Bing Ji Jiu Yi Xue.* 2005;17:619–22.
11. Satas S, Løberg EM, Porter H, Whitelaw A, Steen PA, Thoresen M. Effect of global hypoxia-ischaemia followed by 24 h of mild hypothermia on organ pathology and biochemistry in a newborn pig survival model. *Biol Neonate.* 2003;83:146–56.
12. Kellum JA, Lameire N, KDIGO AKI Guideline Work Group. Diagnosis, evaluation, and management of acute kidney injury: a KDIGO summary (Part 1). *Crit Care.* 2013;17:204.
13. Jetton JG, Boohaker LJ, Sethi SK, Wazir S, Rohatgi S, Soranno DE, et al. Incidence and outcomes of neonatal acute kidney injury (AWAKEN): a multicentre, multinational, observational cohort study. *Lancet Child Adolesc Health.* 2017;1:184–94.
14. Basu RK, Zappitelli M, Brunner L, Wang Y, Wong HR, Chawla LS, et al. Derivation and validation of the renal angina index to improve the prediction of acute kidney injury in critically ill children. *Kidney Int.* 2014;85:659–67.
15. Wazir S, Sethi SK, Agarwal G, Tibrewal A, Dhir R, Bajaj N, et al. Neonatal acute kidney injury risk stratification score: STARZ study. *Pediatr Res.* 2022;91:1141–8.
16. Keles E, Wintermark P, Groenendaal F, Borloo N, Smits A, Laenen A, et al. Serum creatinine patterns in neonates treated with therapeutic hypothermia for neonatal encephalopathy. *Neonatology.* 2022;7:1–9.
17. Rumpel J, Spray BJ, Chock VY, Kirkley MJ, Slagle CL, Frymoyer A, et al. Urine biomarkers for the assessment of acute kidney injury in neonates with hypoxic ischemic encephalopathy receiving therapeutic hypothermia. *J Pediatr.* 2022;241, 133–140.e3.
18. Ikeda T, Murata Y, Quilligan EJ, Parer JT, Murayama T, Koono M. Histologic and biochemical study of the brain, heart, kidney, and liver in asphyxia caused by occlusion of the umbilical cord in near-term fetal lambs. *Am J Obstet Gynecol.* 2000;182:449–57.
19. Karlsson M, Blennow M, Nemeth A, Winblad B. Dynamics of hepatic enzyme activity following birth asphyxia. *Acta Paediatr.* 2006;95:1405–11.
20. Hankins GDV, Koen S, Gei AF, Lopez SM, Van Hook JW, Anderson GD. Neonatal organ system injury in acute birth asphyxia sufficient to result in neonatal encephalopathy. *Obstet Gynecol.* 2002;99:688–91.
21. Choudhary M, Sharma D, Dabi D, Lamba M, Pandita A, Shastri S. Hepatic dysfunction in asphyxiated neonates: prospective case-controlled study. *Clin Med Insights Pediatr.* 2015;9: 1–6.
22. Tarcan A, Tiker F, Güvenir H, Gürakan B. Hepatic involvement in perinatal asphyxia. *J Matern Fetal Neonatal Med.* 2007;20:407–10.
23. Barnett CP, Perlman M, Ekert PG. Clinicopathological correlations in postasphyxial organ damage: a donor organ perspective. *Pediatrics.* 1997;99:797–9.
24. Karlsson M, Satas S, Stone J, Porter H, Thoresen M. Liver enzymes cannot be used to predict liver damage after global hypoxia-ischemia in a neonatal pig model. *Neonatology.* 2009;96:211–8.
25. Chadd MA, Elwood PC, Gray OP, Muxworthy SM. Coagulation defects in hypoxic full-term newborn infants. *BMJ.* 1971;4:516–8.
26. Chessells JM, Wigglesworth JS. Coagulation studies in severe birth asphyxia. *Arch Dis Child.* 1971;46:253–6.
27. Martín-Ancel A, García-Alix A, Cabañas FGF, Burgueros M, Quero J. Multiple organ involvement in perinatal asphyxia. *J Pediatr.* 1995;127:786–93.
28. Schnabl KL, Van Aerde JE, Thomson ABR, Clandinin MT. Necrotizing enterocolitis: a multifactorial disease with no cure. *World J Gastroenterol.* 2008;14:2142–61.
29. Obladen M. Necrotizing enterocolitis — 150 years of fruitless search for the cause. *Neonatology.* 2009;96:203–10.
30. Balyemez G, Sivasli E, Ceylan H, Tutar E, Ekiz S, Tarakcioglu M, et al. Protective effects of Y-27632 on hypoxia/reoxygenation-induced intestinal injury in newborn rats. *J Pediatr Surg.* 2011;46:1490–4.
31. Chen Y, Koike Y, Miyake H, Li B, Lee C, Hock A, et al. Formula feeding and systemic hypoxia synergistically induce intestinal hypoxia in experimental necrotizing enterocolitis. *Pediatr Surg Int.* 2016;32:1115–9.
32. Koike Y, Li B, Ganji N, Zhu H, Miyake H, Chen Y, et al. Remote ischemic conditioning counteracts the intestinal damage of necrotizing enterocolitis by improving intestinal microcirculation. *Nat Commun.* 2020;11:4950.
33. Popescu MR, Panaitescu AM, Pavel B, Zagrean L, Peltecu G, Zagrean AM. Getting an early start in understanding perinatal asphyxia impact on the cardiovascular system. *Front Pediatr.* 2020;8:1–18.
34. Aslam S, Molloy EJ. Biomarkers of multiorgan injury in neonatal encephalopathy. *Biomark Med.* 2015;9:267–75.
35. Nair J, Lakshminrusimha S. Role of NO and other vascular mediators in the etiopathogenesis of necrotizing enterocolitis. *Front Biosci (Schol Ed).* 2019;11:9–28.
36. Gurgul S, Buyukakilli B, Komur M, Okuyaz C, Balli E, Ozcan T. Does levetiracetam administration prevent cardiac damage in adulthood rats following neonatal hypoxia/ischemia-induced brain injury? *Medicina (Lithuania).* 2018;54: 1–15.
37. Barberi I, Calabrò MP, Cordaro S, Gitto E, Sottile A, Prudente D, et al. Myocardial ischaemia in neonates with perinatal asphyxia. *Eur J Pediatr.* 1999;158:742–7.
38. Tapia-Rombo CA, Carpio-Hernández JC, Salazar-Acuña AH, Alvarez-Vázquez E, Mendoza-Zanella RM, Pérez-Olea V, et al. Detection of transitory myocardial ischemia secondary to perinatal asphyxia. *Arch Med Res.* 2000;31:377–83.
39. Szymankiewicz M, Matuszczak-Wleklak M, Vidyasagar D, Gadziński J. Retrospective diagnosis of hypoxic myocardial injury in premature newborns. *J Perinat Med.* 2006;34: 220–5.
40. Sweetman DU, Armstrong K, Murphy JFA, Molloy EJ. Cardiac biomarkers in neonatal hypoxic ischaemia. *Acta Paediatr.* 2012;101:338–43.

41. Hochwald O, Jabr M, Osioich H, Miller SP, McNamara PJ, Lavoie PM. Preferential cephalic redistribution of left ventricular cardiac output during therapeutic hypothermia for perinatal hypoxic-ischemic encephalopathy. *J Pediatr.* 2014;164:999–1004.
42. Yang H, Yao Y, Li W. Injury of myocardial mitochondria in neonatal swines with hypoxic-ischemic brain damage. *Sichuan Da Xue Xue Bao Yi Xue Ban.* 2004;35:39–41.